



The Prophylactic Extraction of Third Molars: A Public Health Hazard

Jay W. Friedman, DDS, MPH

Ten million third molars (wisdom teeth) are extracted from approximately 5 million people in the United States each year at an annual cost of over \$3 billion.

In addition, more than 11 million patient days of “standard discomfort or disability”—pain, swelling, bruising, and malaise—result postoperatively, and more than 11000 people suffer permanent paresthesia—numbness of the lip, tongue, and cheek—as a consequence of nerve injury during the surgery. At least two thirds of these extractions, associated costs, and injuries are unnecessary, constituting a silent epidemic of iatrogenic injury that afflicts tens of thousands of people with lifelong discomfort and disability.

Avoidance of prophylactic extraction of third molars can prevent this public health hazard. (*Am J Public Health*. 2007; 97:1554–1559. doi:10.2105/AJPH.2006.100271)

IN THE UNITED STATES, prophylactic removal of third molars (wisdom teeth) is advocated by almost all oral and maxillofacial surgeons and many general dentists. According to the American Association of Oral and Maxillofacial Surgeons, “if there is insufficient anatomical space to accommodate normal eruption . . . removal of such teeth at an early age is a valid and scientifically sound treatment rationale based on medical necessity.”¹ As a result, 10 million teeth classified as impactions (teeth that fail to erupt into normal position but remain fully or partially embedded and covered by jawbone or gum tissue) are removed every year from mostly healthy young people.²

There is no evidence of widespread third-molar infection and pathology or of medical necessity to justify so much surgery. In fact, 50% of upper third molars classified as impactions are

normally developing teeth, most of which will erupt with minimal discomfort if not extracted prematurely. Only 12% of truly impacted teeth are associated with pathological conditions such as cysts and damage to adjacent teeth.^{3,4} Most discomfort of erupting wisdom teeth is equivalent to teething and disappears on full eruption. Most infection of the gum tissue around the erupting or partially erupted teeth can be prevented by good oral hygiene, including toothbrushing. Infection occurs in fewer than 10% of third molars, most of which can be cured with antibiotics, oral rinsing, or removal of excess tissue (the hyperplasia) around the tooth, without requiring removal of the tooth itself.⁵ Most of the pain and illness attributed to third molars is caused by the surgery, not the teeth.

Third-molar surgery is a multibillion-dollar industry that

generates significant income for the dental profession, particularly oral and maxillofacial surgeons. It is driven by misinformation and myths that have been exposed before but that continue to be promulgated by the profession.⁶

THE MYTHOLOGY OF WISDOM TEETH

Myth Number 1—Third Molars Have a High Incidence of Pathology

Not more than 12% of impacted teeth have associated pathology (Table 1). This incidence is the same as for appendicitis (10%) and cholecystitis (12%), yet prophylactic appendectomies and cholecystectomies are not the standard of care.⁴ Why then prophylactic third-molar extractions?

What about pericoronitis, the pain and infection of the gum tissue surrounding a partially



TABLE 1—Pathologies and Pericoronitis Associated With Impacted Third Molars

Pathology	Percentage Affected
Internal resorption	0.85
Cysts	1.65
Periodontal bone loss	4.72
Resorption on distal surface of second molar	4.78
Pericoronitis	8
Total	20

Source. See references 3, 5, 7, and 8.

erupted or erupted third molar? Excluding the normal discomfort of teething as the tooth erupts, the incidence of inflammation and infection of the gum tissue ranges from 6% to 10%.^{5,7,8} Adding an average of 8% incidence of pericoronitis to the 12% pathology listed in Table 1 brings the maximum pathology associated with third molars to 20%. However, a single episode of pericoronitis is not a reason to remove a third molar; this should be considered only if the problem fails to respond to conservative treatment or recurs.⁹

Many dentists confuse the incidence of pathology as it shows up in their offices with its prevalence in the population. Advocacy of prophylactic extractions that is based on anecdotal experience (i.e., patients with diseased third molars who make dental appointments) exaggerates the problem and exposes millions of people to the risk of iatrogenic injury. Considering the low

prevalence of third-molar pathology in the population, removal of asymptomatic, nonpathologic third molars does not meet the standard of evidence-based practice.

Myth Number 2—Early Removal of Third Molars Is Less Traumatic

The American Association of Oral and Maxillofacial Surgeons states that “about 85% of third molars will eventually need to be removed.”^{10(p3)} The association recommends extraction of all 4 third molars by young adulthood—preferably in adolescence, before the roots are fully formed—to minimize complications such as postextraction pain and infection.

Early removal of third molars is actually more traumatic and painful than leaving asymptomatic, nonpathologic teeth in situ. Tulloch et al. estimate that patients suffer an average of 2.27 days of standard discomfort or disability, defined as “the

disability normally associated with an uncomplicated surgical extraction of a mandibular third molar: namely, pain, swelling, bruising and malaise.”^{11(p507)} Furthermore, dry socket, secondary infection, and paresthesia are less likely to occur in persons aged 35 to 83 years than in those aged 12 to 24 years, who experience more third-molar extractions. The highest risk of complication is in persons aged 25 to 34 years.⁷

When a lower third molar is removed, usually the opposing upper third molar is also removed. Assuming an average of 2 extractions per episode, the 10 million third molars extracted annually involve 5 million people and 11.36 million days of standard discomfort or disability (Table 2). If only the 20% of wisdom teeth with pathology were extracted, 4 million people would be spared pain, swelling, bruising, malaise, and consequent absence from school or work—an aggregate

decrease of 9 million days of discomfort and disability each year. Allowing for some margin of error and for the fact that one third of third molars are reported to cause some symptoms in the past or present, if only 33% were extracted, 3.34 million people would still be spared an average of 2.27 days of discomfort and disability each, or 7.6 million days of discomfort and disability in the aggregate (Table 3).

Myth Number 3—Pressure of Erupting Third Molars Causes Crowding of Anterior Teeth

It is not possible for lower third molars, which develop in the spongy interior cancellous tissue of bone with no firm support, to push 14 other teeth with roots implanted vertically like the pegs of a picket fence so that the incisors in the middle twist and overlap. Yet that is the reason often given for removal of third molars, even though studies have produced

TABLE 2—Estimated Third-Molar Extractions Per Year, by Doctor Performing Extraction: United States

	No. of Extractions	Cost, ^a \$	No. of Patients	No. of Lower Third-Molar Extractions	Patient Days of Standard Discomfort or Disability ^b
Oral and maxillofacial surgeons	7 000 000	2 852 500 000	3 500 000	3 500 000	7 950 000
General practitioners	3 000 000	450 000 000	1 500 000	1 500 000	3 410 000
Total	10 000 000	3 302 500 000	5 000 000	5 000 000	11 360 000

Source. See reference 2.

^aEstimate based on an average fee of \$500 for 1 upper and 1 lower third-molar extraction for oral and maxillofacial surgeons, \$75 for radiographs, \$300 for general anesthesia or intravenous sedation in 80% of cases, and \$300 for an upper and lower third-molar extraction for general practitioners. According to these estimates, the average income from third-molar extractions for 5500 oral and maxillofacial surgeons would be \$518 636.

^bAverage per patient is 2.27 days.



TABLE 3—Estimated Annual Reduction of Cost and Disability From Performing Only Needed Third-Molar Extractions: United States

	No. of Extractions	Cost, \$	Savings, \$ ^a	No. of Patients	Patient Days of Standard Discomfort or Disability	Reduction of Patient Days of Standard Discomfort or Disability
Oral and maxillofacial surgeons	2 310 000	941 325 000	1 911 175 000	1 160 000	2 630 000	5 320 000
General practitioners	1 000 000	150 000 000	300 000 000	500 000	1 130 000	2 280 000
Total	3 310 000	1 091 325 000	2 211 175 000	1 660 000	3 760 000	7 600 000

Source. See reference 2.

Note. Extractions because of pathological conditions are estimated to represent 33% of current annual third-molar extractions.^{20,21}

^aSavings are calculated by subtracting the estimated cost of third-molar extractions performed only in cases in which pathology is present from the estimated cost of extractions currently performed per year.

contrary evidence.^{12–14} Third molars do not possess sufficient force to move other teeth. They cannot cause crowding and overlapping of the incisors, and any such association is not causation.

Myth Number 4—The Risk of Pathology in Impacted Third Molars Increases With Age

The American Association of Oral and Maxillofacial Surgeons states, without substantiation, “Pathologic conditions [of impacted third molars] are generally more common with an increase in age.”^{1(p2)} A study of more than 1756 patients who had retained more than 2000 mandibular impactions for an average of 27 years found that only 0.81% experienced cystic formation. There is no evidence of a significant increase in third-molar pathology with age.³ Of course, teeth that become repeatedly symptomatic or develop associated pathology should be removed.^{15,16}

Myth Number 5—There is Little Risk of Harm in the Removal of Third Molars

Given the low incidence of pathology, it is specious to contend that less than 3 days of temporary discomfort or disability is a small price to pay to avoid the future risks of root resorption, serious infections, and cysts. Also ignored is the risk of

incidental injury such as broken jaws, fractured teeth, damage to the temporomandibular joints, temporary and, especially, permanent paresthesia or dyesthesia (numbness and dysfunction of the lower lip and the tongue). The box on the following page lists the complications that can occur with the removal of wisdom teeth.

Complications of Third-Molar Extractions

- Pain
- Swelling
- Trismus
- Hemorrhage
- Alveolar osteitis (dry socket)
- Periodontal damage
- Soft-tissue infection
- Injury to temporomandibular joint
- Malaise
- Temporary paresthesia (numbness of the lips, tongue, and cheek)
- Permanent paresthesia
- Fracture of adjacent teeth
- Fracture of the mandible
- Fracture of the maxilla
- Sinus exposure or infection
- Anesthetic complications

Data on the number of fractured jaws and damaged teeth are lacking. Fractures occur but are uncommon. There is little data on temporary and permanent temporomandibular joint injury after third-molar surgery, although a recent study of patients aged 15 to 20 years reported an incidence of 1.6%, which translates to thousands of such injuries each year.¹⁷ However, mandibular and lingual nerve injury resulting from third-molar surgery has been more widely reported. Because the percentages of incidental (unavoidable) and iatrogenic (avoidable) injury are small, no one has previously performed the simple task of applying these figures to the entire population exposed to surgery.

Reports on the incidence of mandibular (lower jaw) nerve paresthesia vary from a low of 1.3% for temporary and 0.33% for permanent paresthesia to a high of 4.4% for temporary and 1% for permanent paresthesia.^{18,19} Small figures, indeed! But if 3.5 million lower third molars are removed from 3.5 million persons by oral and maxillofacial surgeons (Table 2), the incidence of permanent paresthesia ranges from a low of more than 11 500 to a high of 35 000. Two thirds of these patients had no present or previous symptoms to warrant extraction.^{20,21} If 67% of the surgery is unnecessary, then between 7739 and 23 450 people are afflicted with permanent paresthesia unnecessarily each year (Table 4).

These figures are based on simple extrapolations from studies by



TABLE 4—Estimated Annual Incidence of Paresthesia of the Mandibular Nerve Following Third-Molar Extractions by Oral and Maxillofacial Surgeons: United States

Persons with Paresthesia	Minimum No	Maximum No.
Extraction of 3.5 million lower third molars		
Temporary	45 500	154 000
Permanent	11 550	35 000
Extraction of the 33% of third molars with symptoms or pathology		
Temporary	15 015	50 820
Permanent	3 811	11 550
Incidence of iatrogenic paresthesia if 67% of the extractions are unnecessary		
Temporary	30 485	103 180
Permanent	7 739	23 450
Incidence of iatrogenic paresthesia if 50% of the extractions are unnecessary		
Temporary	22 750	77 000
Permanent	5 775	17 500

Note. Paresthesia is numbness of the lips, tongue, and cheek. The estimated minimum percentage of temporary cases of paresthesia is 1.3% and of permanent cases is 0.33%—the maximum is 4.4% temporary and 1% permanent.

independent researchers, many of whom are oral and maxillofacial surgeons and therefore should be credible. Most of the paresthesias derive from third-molar surgery performed by oral and maxillofacial surgeons because they perform most third-molar extractions, including those at a high risk of nerve injury.

A recent study reported that 25% of erupted third molars may have deep periodontal pockets that are considered an indicator of periodontal disease.²² Many of these are pseudopockets consisting of excess gum tissue that can be treated conservatively or reduced surgically, rather than extracted, as is done for other teeth with this condition. Nonetheless, let us assume that the incidence of third-molar

pathology has been underrepresented in the other cited studies and that 50% of third-molar extractions, including those with deep periodontal pockets, are justified. In that case, among the other 50% there would be 5775 to 17 500 individuals with permanent mandibular paresthesia every year. And this does not include lingual (tongue) nerve paresthesia, which may occur as frequently as once in 10 000 mandibular extractions, adding another 350 to 500 paresthesia cases a year.²³ At this rate, between 57 000 and 175 000 persons in the United States have been afflicted with permanent paresthesia over the past 10 years as a consequence of unnecessary prophylactic third-molar extractions.

PARESTHESIA

How is it possible that so much harm is done and so little is heard of it? The answer is that paresthesia of the lips and tongue is not deadly. Although it is one of the most common reasons that patients sue oral and maxillofacial surgeons, most judges and jurors do not fault the surgeons, because the patients consented to surgery, thereby assuming the risk. That patients are given unsubstantiated information that would, in just circumstances, invalidate their informed consent is rarely convincing to a court.^{24,25} Patients who might have avoided the surgery in the absence of confirmed pathology are consigned to a numb jaw or lip or tongue for the rest of their lives. Symptoms include frequent drooling, biting of the lip or the inside of the cheek or the side of the tongue, and paralytic disfigurement or drooping of the lip. The sense of taste, the facility of speech, and the sensory pleasure of kissing are diminished. When bilateral paresthesia occurs, the anguish, discomfort, and disability

are more than doubled. To be sure, the degree of paresthesia varies, from mild to severe. Constant tingling numbness is the most common feature, but some patients experience frequent shooting pains much like neuralgia. Those suffering from severe paresthesia may be driven to near hysteria by a loss of sensory functions that affects all aspects of their lives.

The risk of paresthesia is not the same for all extractions. It is highest for the mesioangular impaction, in which the tooth is positioned at a 30–45° angle toward or actually against the distal, or back, surface of the second molar (Figure 1).

When fully formed, the roots frequently lie close to the right and left mandibular nerves, which run along the jaw beneath or between the roots. The risk of permanent paresthesia following extraction of a mesioangular impaction is as high as 6.8%, much higher than for other types of unerupted or impacted teeth.⁶ More than 95% of these teeth will never cause any problem. As many as

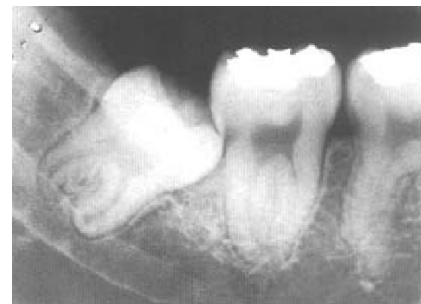

FIGURE 1—A mesioangular impaction, with the roots in close proximity to or saddling the mandibular canal containing the mandibular nerve.

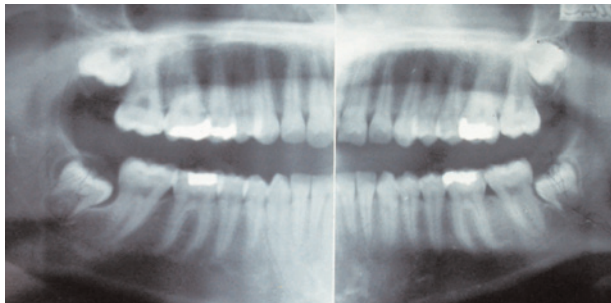


FIGURE 2—Panographic radiograph of 4 normally developing wisdom teeth, classified as full bony impactions at the time of extraction.

three fourths of the developing third molars classified as mesioangular impactions at the time of extraction are not impacted at all, but would continue to erupt into normal position in the mouth if left alone.²⁶

There can be no excuse for tolerating so many unnecessary extractions on millions of unsuspecting and misled people and putting them at risk of so much iatrogenic nerve injury. This is a public health hazard.

THE ECONOMICS OF THIRD-MOLAR SURGERY

Each of the approximately 5500 oral and maxillofacial surgeons in private practice averages nearly 53 third-molar cases a month, accounting for the removal of at least 7 of the 10 million “impacted” third molars extracted annually.²⁷ Most of these teeth are not impacted. Half are upper third molars, most of which can erupt normally, as will many, if not most, of the lower third molars (Figure 2). Removing these teeth while they are

still developing in the jaw bone results in a higher fee: extraction when the tooth is embedded in soft tissue or bone is a more complex surgical procedure than a simple extraction after the tooth erupts. Even so, it seldom takes an oral and maxillofacial surgeon more than 8 minutes to extract an impacted tooth once the patient is anesthetized.²⁸

The average annual income of oral and maxillofacial surgeons from third-molar extractions alone is estimated at \$518 636 (see footnote, Table 2). Even though only 20% of third molars have associated pathology or tissue inflammation, allowance should be made for the 33% that may cause some discomfort (Table 3), even if the condition might resolve later on without surgery. Two thirds of all third-molar extractions are unnecessary. Eliminating these extractions would reduce the oral and maxillofacial surgeon’s annual income by \$347 486, resulting in an annual savings to patients of more than \$1.9 billion, or \$2.2 billion if extractions by general

practitioners are included (Table 3).

A RATIONAL POLICY

The British National Institute for Clinical Excellence is unequivocal in its recommendation, adopted by the National Health Service: “The practice of prophylactic removal of pathology-free impacted third molars should be discontinued. . . . There is no reliable evidence to support a health benefit to patients from the prophylactic removal of pathology-free impacted teeth.”^{9(p1–2)} The conditions for which extraction is justified include nonrestorable dental caries, pulpal infection, cellulitis, recurrent pericoronitis, abscesses, cysts, and fractures.

Government-funded programs in the United States are beginning to adopt similar policies; an example is the Healthy Kids Dental Program administered by Delta Dental of Michigan. Also needed is better education of dentists, beginning in dental school, and of the public on the reasons to avoid unnecessary extractions.

THE FALLACY OF TWO SCHOOLS OF THOUGHT

One school of thought is endorsed by oral and maxillofacial surgeons who contend that most third molars are potentially pathologic and should be removed. The other holds that only third molars with associated pathology should be removed. The legal system, in which decisions are generally based on norms of practice or local or regional standards of care, credits each school of

thought as having equal merit, ignoring the scientific evidence base. That is why oral and maxillofacial surgeons usually prevail in malpractice suits when patients are injured during elective surgery. After all, if the expert oral and maxillofacial surgeon says the surgery is necessary, then it is necessary. The fact that most third molars, impacted or not, do not become diseased and that the risk of iatrogenic injury from such surgery is greater than the risk of leaving asymptomatic, nonpathologic teeth alone does not override the expert opinion of oral and maxillofacial surgeons. Thus, the prevalent practice of prophylactic third-molar extractions is ordained as the standard of care, even though that standard is based on an erroneous evaluation of all outcomes and costs.

Malpractice in dentistry is more common than is acknowledged, but the victim’s recourse to redress the physical and financial injury is severely limited.²⁵ The recovery amounts involved are usually too small to cover an attorney’s expenses. However, there is something the legal profession could do to protect the public: abolish the fallacy of the standard of care and 2 schools of thought, which ignores evidence-based science and perpetuates and forgives malpractice.

The evidence is compelling that prophylactic extraction of third molars is a significant public health hazard. It is a silent epidemic of iatrogenic injury that warrants avoidance of the extraction of any third molar in the absence of a pathologic condition or a specific problem. ■



About the Author

Jay W. Friedman is a retired general dentist and a consultant and writer living in Los Angeles, Calif.

Requests for reprints should be sent to Jay W. Friedman, 3057 Queensbury Dr, Los Angeles, CA 90064 (e-mail: drjfriedman@sbcglobal.net).

This article was accepted September 20, 2006.

Human Participation Protection

No protocol approval was needed for this study.

References

1. *Statements by the American Association of Oral and Maxillofacial Surgeons Concerning the Management of Selected Clinical Conditions and Associated Clinical Procedures: The Management of Impacted Third Molar Teeth*. Rosemont, Ill: American Association of Oral and Maxillofacial Surgeons; 2007.
2. American Dental Association. 1999 survey of dental services rendered [unpublished report]. ADA Catalog No. SDSA-1999.
3. Stanley HR, Alattar M, Collett WK, Stringfellow HR, Spiegel EH. Pathological sequelae of "neglected" impacted third molars. *J Oral Pathol*. 1988;17:113-117.
4. Leonard MS. Removing third molars: a review for the general practitioner. *J Am Dent Assoc*. 1992;123:77-92.
5. Hold on to your wisdom teeth. *Consum Rep Health*. 1993;5(8):84-85.
6. Friedman JW. Containing the costs of third-molar surgery: a dilemma for health insurance. *Public Health Rep*. 1983;98:379-384.
7. Osborn TP, Frederickson G, Small IA, Torgerson TS. A prospective study of complications related to mandibular third molar surgery. *J Oral Maxillofac Surg*. 1985;43:767-769.
8. Von Wowern N, Nielson HO. The fate of impacted lower third molars after the age of 20. A four year clinical follow up. *Int J Oral and Maxillofac Surg*. 1989;18:277-280.
9. National Institute for Clinical Excellence. Guidance on the extraction of wisdom teeth. 2000. Available at: <http://www.nice.org.uk>. Accessed June 14, 2007.
10. Wisdom teeth [pamphlet]. Rosemont, Ill: American Association of Oral and Maxillofacial Surgery; 2005.
11. Tulloch JFC, Antczak-Bouckoms AA, Ung N. Evaluation of the costs and relative effectiveness of alternative strategies for the removal of mandibular third molars. *Int J Technol Assess Health Care*. 1990;6:505-515.
12. Southard TE. Third molars and incisor crowding: when removal is unwarranted. *J Am Dent Assoc*. 1992;123:75-79.
13. Kaplan RG. Mandibular third molars and post-retention crowding. *Am J Orthodont*. 1974;66:411-430.
14. Harradine NW, Pearson MH, Toth B. The effect of extraction of third molars on late lower incisor crowding: a randomized controlled trial. *Br J Orthodont*. 1998;25:117-122.
15. Edwards MJ, Brickley MR, Goodey RD, Sheperd JP. The cost, effectiveness, and cost-effectiveness of removal and retention of asymptomatic, disease free third molars. *Brit Dent J*. 1999;187:380-384.
16. Song F, O'Meara S, Wilson P, Golder S, Kleijnen J. The effectiveness and cost-effectiveness of prophylactic removal of wisdom teeth. *Health Technol Assess*. 2000;4:1-55.
17. Haug GJ, Rue TC. Third-molar extractions as a risk factor for temporomandibular disorder. *J Am Dent Assoc*. 2006;137:1547-1554.
18. Valmaseda-Castellon E, Berini-Aytes L, Gay-Escoda C. Inferior alveolar nerve damage after lower third molar surgical extraction: a prospective study of 1117 surgical extractions. *Oral Surg Oral Med Oral Pathol Oral Radiol Endod*. 2001;92:377-383.
19. Kipp DP, Goldstein BH, Weiss WW. Dyesthesia after mandibular third molar surgery. *J Am Dent Assoc*. 1980;100:185-192.
20. Slade GD, Foy SP, Sugars DA, Phillips C, White RP. The impact of third molar symptoms, pain, and swelling on oral health-related quality of life. *J Oral Maxillofac Surg*. 2004;62:1118-1124.
21. Mettes TG, Nienhuijs ME, van der Sanden WJ, Verdonschot EH, Plasschaert AJ. Interventions for treating asymptomatic impacted wisdom teeth in adolescents and adults. *Cochrane Database Syst Rev*. 2005 Apr 18;(2): CD003879.
22. Blakey GH, Marciani RD, Haug RH, et al. Periodontal pathology associated with asymptomatic third molars. *J Oral Maxillofac Surg*. 2002;60:1227-1233.
23. Bacchetti P, Pogrel MA. Frequency of trigeminal nerve injuries following third molar removal. *J Oral Maxillofac Surg*. 2005;63:732-735.
24. Friedman JW, Atchison KA. The standard of care: an ethical responsibility of public health dentistry. *J Public Health Dent*. 1993;53:165-169.
25. Friedman JW. 20th century dental (mal)practice in the 21st century. *J Calif Litigation*. 2004;17:37-40.
26. Hattab FN. Positional changes and eruption of impacted mandibular third molars in young adults: a radiographic 4-year follow-up study. *Oral Surg Oral Med Oral Pathol Radiol Endod*. 1997;84:604-608.
27. Moore PA, Nahouraii HS, Zovko JG, Wisniewski SR. Dental therapeutic practice patterns in the US. I. Anesthesia and sedation. *Gen Dent*. 2006;54:92-98.
28. MacGregor AJ. *The Impacted Lower Wisdom Tooth*. New York, NY: Oxford University Press; 1985.